The critical airway, rescue ventilation, and the Combitube: Part 2

James M. Rich, CRNA, MA
Dallas, Texas

Andrew M. Mason, MB, BS, MRCS, LRCP
Ipswich, England

Tareg A. Bey, MD
Orange, California

Peter Krafft, MD, PhD
Michael Frass, MD
Vienna, Austria

Emergency and unexpected difficult airway management can rapidly deteriorate into a critical airway event (eg, inadequate mask ventilation, failed tracheal intubation, or cannot ventilate–cannot intubate). Recommended options to resolve a critical airway event include the laryngeal mask airway, the esophageal tracheal Combitube (ETC; Tyco-Healthcare-Nellcor, Pleasanton, Calif), transtracheal jet ventilation, or a surgical airway to avoid potential neurological disability or death.

Part 1, which was published in the February 2004 AANA Journal*, reviewed use of the ETC in combination with the self-inflating bulb and/or portable carbon dioxide detector as an effective rescue airway system. Important aspects of rescue ventilation, ETC training methods, how to use the ETC, and determining ETC location also were reviewed.*

Part 2 reviews ETC advantages, contraindications, and reported complications in prehospital, emergency medicine, and anesthesia settings. Safe methods to exchange the ETC for a definitive airway also are described. Major ETC advantages include the following: (1) easy to learn, (2) can be inserted rapidly, (3) effectively secures the airway, (4) provides adequate lung ventilation, (5) minimizes aspiration risks, (6) facilitates application of high ventilatory pressures, and (7) can be exchanged safely for a definitive airway without compromising airway control or protection.

Key words: Airway complications, combat casualty core, Combitube, failed intubation, rescue ventilation.

Combitube advantages

The esophageal-tracheal Combitube (ETC; Tyco-Healthcare-Nellcor, Pleasanton, Calif) has multiple advantages and can be used by virtually any provider, independent of level of training or expertise (Table 1).

• *Use by personnel untrained in airway management.* The ease of use of the ETC has been reconfirmed recently.[15] The ETC can facilitate prompt and effective airway management from the prehospital setting[16] through admission to the emergency department[17] and beyond.[9,18,19] When tracheal intubation is difficult or impossible,[9-13,16,20-36] due to lack of equipment or expertise, the ETC can control and protect the airway of an unconscious patient who is at risk of airway obstruction (Figure 1).[4-6,13,16,29,31]

In a prospective study, nurses untrained in tracheal intubation accomplished blind insertion and ventilation with the ETC faster than physicians skilled in performing tracheal intubation using direct laryngoscopy.[27] The ability of personnel untrained in direct laryngoscopy and tracheal intubation to rapidly acquire the skill necessary to use the ETC is a major advantage.[14,30,32,37]

• *Decreased risk of pulmonary aspiration.* The ETC also minimizes the risk of pulmonary aspiration.[7] The 2-tube, 2-cuff design aids in protecting the airway from gastric contents, blood, and debris.[4-7,21,38-40] In the esophageal position, the unused tracheal (distal) lumen decreases the risk of aspiration by immediately decompressing the stomach[41] and providing a route for evacuation of gastric fluid and small particulate matter.[27,42] Investigators in a large prehospital study (n = 831) reported that the small number of patients in their study who had signs of pulmonary aspiration at autopsy was in accordance with the growing body of evidence on the safety of the ETC with regard to aspiration.[39] In addition, the stomach can be directly suctioned through port No. 2 (Figure 2) in the esophageal position with the suction catheter that is packaged with the ETC. The ETC helps prevent aspiration by sealing the esophagus instead of the trachea.[7] In the tracheal position, it seals like an endotracheal tube (ETT).

• *Sealing capacity of the ETC during general anesthe-*

Table 1. Advantages of the esophageal-tracheal Combitube (ETC)[1-14]

- Advantageous with patients in whom manipulation of the cervical spine is hazardous or impossible (trauma, suspected cervical spine injury, rheumatoid arthritis)
- Aspiration protection comparable to tracheal intubation
- Can be inserted using a blind technique or a laryngoscope
- Can be used by persons untrained in tracheal intubation who are responsible for ventilating the patient before the arrival of trained individuals (ie, first responders)
- Controlled mechanical ventilation possible at high ventilation pressures
- Neck flexion unnecessary; neutral head position best
- No preparation of ETC necessary; tube and syringes ready to use
- Noninvasive compared with cricothyrotomy
- Placement and fixation secure and simultaneous after inflation of oropharyngeal cuff
- Provides airway control for failed intubation due to lack of skill, equipment limitations, or anatomical abnormality
- Provides rapid ventilation for paralyzed patients who cannot be intubated or mask ventilated
- Provides rescue of a failed intubation secondary to an unexpected difficult airway
- Quick and easy-to-use emergency airway device
- Superior sealing of the airway
- Tracheal (rare) and esophageal (common) placement work equally well
- Use by persons previously trained in tracheal intubation who have infrequent opportunity to maintain their skills
- Useful whenever access to the patient's head is difficult (eg, confined space rescue situation).
- Ventilation with the ETC in the esophageal position produces higher plasma oxygen tensions than in patients ventilated with tracheal tubes.
- Well suited for use with obese patients

sia. Studies during general anesthesia in fasting patients have confirmed the superior sealing capacity of the ETC in the esophageal position.[4-6,40,43] An air-tight seal was maintained at airway pressures of up to 30 cm of H_2O during peritoneal carbon dioxide inflation and steep Trendelenburg position.[4] Several of these studies demonstrated the superior sealing capacity of the ETC while using less than the recommended volume of air in the oropharyngeal cuff.[5,6] To date, only 1 study[40] stands in contrast to studies by Hartmann et al,[4] Urtubia et al,[5] and Hoerauf et al[6] with regard to airway sealing with the ETC. In a study by Mercer,[40] 2 (7%) of 27 patients with methylene blue instilled into their mouths after ETC insertion showed tracheal soiling after ETC extubation. Frass et al[43] also reported air-tight sealing of the device in a review of 500 cases. Even though the studies by Hartmann et al,[4] Urtubia et al[5] and Hoerauf et al[6] substantiate the superior sealing capability of the ETC at lower cuff volumes, it remains essential to use the manufacturer's recommended cuff-inflation volumes for the Combitube, 100 mL, and Combitube small adult (SA), 85 mL, to seal the proximal oropharyngeal cuff in emergency situations. This will help ensure that maximal sealing is achieved and minimize the risk of pulmonary aspiration.

Figure 1. The esophageal-tracheal Combitube (Tyco-Healthcare-Nellcor, Pleasanton, Calif)

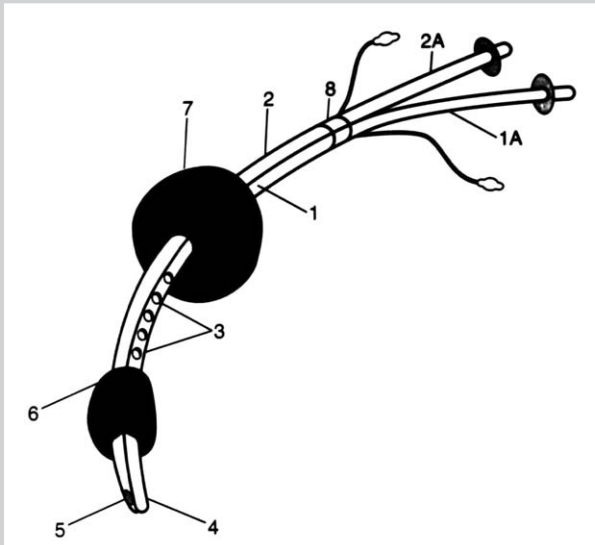

(1) "Esophageal obturator" or "pharyngeal" lumen; (1A) short tube for lumen 1; (2) "tracheal" or "tracheoesophageal" lumen; (2A) short tube for lumen 2; (3) perforations of lumen 1; (4) distal blind end of lumen 1; (5) open end of lumen 2; (6) distal cuff; (7) pharyngeal balloon; (8) printed rings indicating depth of insertion.

(Used with permission from Frass et al).[20]

Figure 2. Esophageal-tracheal Combitube in the esophageal position

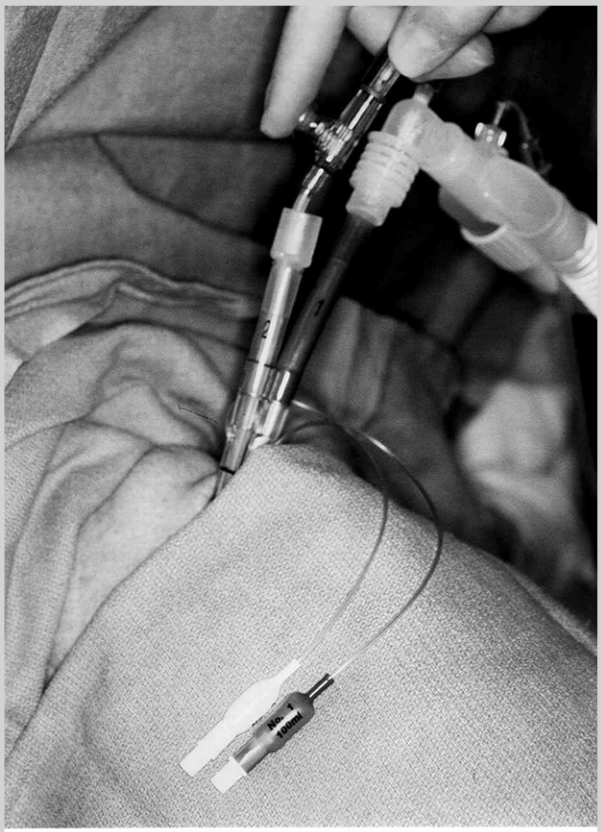

In the esophageal position, the unused tracheal lumen also helps decrease the likelihood of aspiration by decompressing the stomach and providing a route for evacuation of gastric fluid.

(Used with permission from Airway Education & Research Foundation [www.AirwayEducation.com] Dallas, Tex.)

• *Ventilation capacity of the ETC.* Evidence also exists that the ETC facilitates lung ventilation compared with that provided with an ETT.[9,44] Studies have shown it to be adequate for lung ventilation during cardiopulmonary resuscitation (CPR)[9] and adequate for mechanical ventilation in the intensive care unit[18] and during tracheotomy.[19] In addition, patients ventilated via an esophageally placed ETC generated a higher arterial oxygen tension (Pa_{O_2}) than patients ventilated with a correctly placed ETT under identical ventilation parameters. It is surmised that the higher Pa_{O_2} is caused by a smaller inspiratory rising pressure, the formation of a small auto positive end expiratory pressure, and a slightly prolonged exhalation phase, which is attributed to the small pharyngeal perforations (side ports or ventilating eyes) in the esophageal (proximal) lumen of the ETC.[2,9] In contrast with the Proseal laryngeal mask airway or LMA (LMA North America, San Diego, Calif) and laryngeal tube, Hartmann et al[44] reported that ventilatory support and sealing capacity of up to 30 cm of H_2O were sufficient only in the ETC and tracheal tube in 100% of patients having laparoscopic surgery. In addition, airway pressures during ventilation up to 50 cm of H_2O using the ETC were described by Frass et al.[43]

• *Use of the ETC in prehospital care.* Reports of the ETC being used for prehospital airway management continue to grow, which increases the likelihood that patients may arrive at the hospital with the ETC in place. Therefore, this makes it all the more crucial for anesthesia providers to be familiar with how the ETC functions.[12,22,24,28-30,33,34,36,39,45,46] An initial study that evaluated the ability of rural paramedics to use the ETC as a primary or rescue airway confirmed that one of the most important factors for successful ETC insertion is comprehensive training and continuing education.[8,24] The low level of successful insertion (64% as a rescue device for failed intubation and 71% as a primary airway device) was attributed to training flaws in regard to ETC insertion angle, depth of insertion, and cuff inflation sequence.[24] Poststudy analysis revealed that had more initial training been applied to these 3 key points, all but 1 of the failed 16 insertions probably would have been successful.[24]

A study involving 500 emergency medical technicians (EMTs) trained in defibrillation with no intubation skills (receiving only manikin training) showed an overall successful ETC insertion rate of 79% despite only 195 patients in cardiac arrest during an 18-month period.[34] Lefrancois and Dufour[39] studied 831 blind ETC insertions by prehospital EMTs trained in defibrillation (no intubation skills) and reported a successful placement rate of 95.4% with a successful ventilation rate of 91.4%. Of the 25 reported cases of inadequate ventilation (3.0% of 831), 16 were a result of the wrong ETC port being used for ventilation (1.9% of 831). The reliability and efficacy of the homemade, syringe-type esophageal detector device that was used to determine the correct port through which to ventilate was not discussed by the authors. The device was fashioned from parts not designed to be used as an esophageal detector device. A loose fit in any of the homemade esophageal detector device's 4 connecting parts could have decreased the necessary sealing capability and potentially allowed easy aspiration of air through port No. 2, even with the ETC in the esophageal position (eg, creation of a false-positive). Whether or not this was a contributory factor in selecting the wrong port for ventilation is indeterminable.[39]

Another prospective study demonstrated the ability of flight nurses (receiving only didactic and videotape

Figure 3. Prehospital use of the Combitube

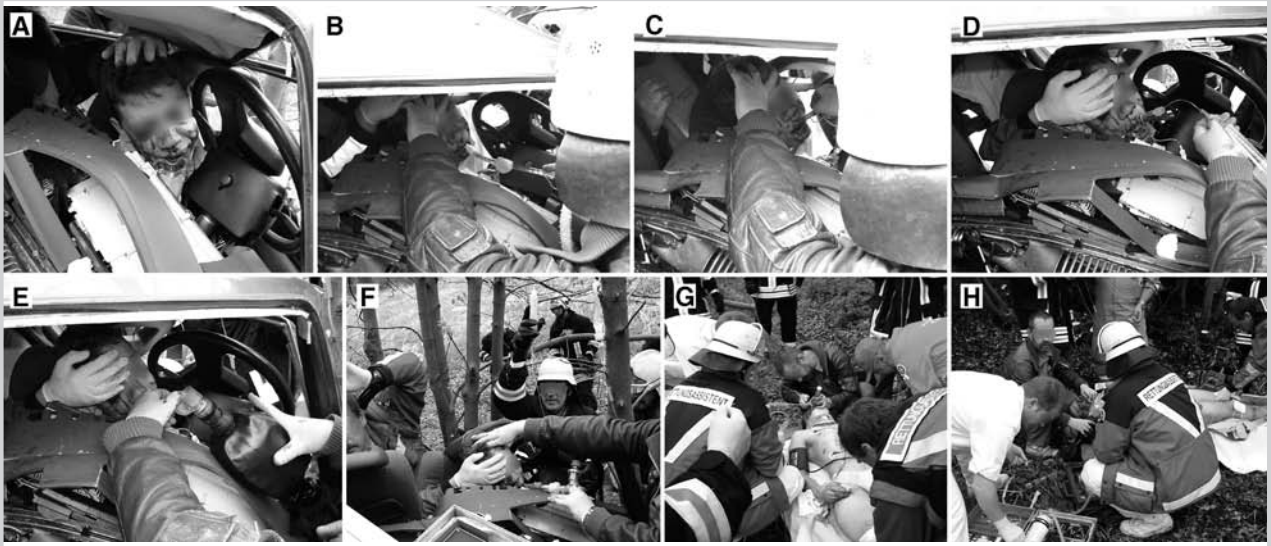

Multiple trauma patient with head injury (Glasgow Coma Scale score, <8) and face hemorrhage, as well as lower extremity fracture with a systolic blood pressure of 60 mm Hg, heart rate of 120 beats per minute, and Spo_2 not registering. Patient required urgent closed-space rescue and extrication from motor vehicle crash. Projected time for extrication estimated at greater than 20 minutes. Because his head was trapped between the seat and steering wheel, a cervical collar could not be applied. Also, inaccessibility and oral hemorrhage prevented use of tracheal intubation. Because the patient was minimally responsive with an intact gag reflex, ketamine and midazolam were administered intravenously to facilitate blind insertion of the esophageal-tracheal Combitube (ETC). (A) Preoxygenation with nonrebreathing mask. (B and C) Blind ETC insertion through open front windshield. (D) Inflation of ETC cuffs. (E) Lung ventilation with ETC and resuscitation bag. (F) Patient removed from vehicle with airway secured by ETC. (G) ETC exchanged for a tracheal tube using direct laryngoscopy. (H) Ventilation using resuscitation bag and endotracheal tube. (Note the ETC lying on the ground.)

(Used with permission. Copyright Dr. med. Peer-G. Knacke, Ostholstein-Kliniken Eutin, Eutin, Germany.)

instruction along with manikin training) to successfully insert the ETC after 2 or more failed attempts at rapid-sequence intubation in patients with mandible fractures, facial trauma, and/or traumatic brain injury. All ETC insertions were successful, and no patient died as a result of failure to control the airway.[33]

Investigators in another prehospital study found the ETC to have fewer problems and greater efficacy than the pharyngeal tracheal lumen airway (PTLA), the LMA, and the oral airway–mask when used by EMTs during prehospital cardiorespiratory arrest. In addition, the overall rate of successful insertion and adequate ventilation was higher with the ETC group (86% successful insertion rate), despite the fact that some of the EMTs had received training on the LMA in the operating room but only manikin training with the ETC.[30] The ETC group had a lower mean Pa_{CO_2}, a higher Pa_{O_2}, and a higher mean exhaled volume[30] than the PTLA, LMA, and oral airway–mask groups. In contrast with the LMA and PTLA groups, no patients experienced aspiration in the ETC group. EMTs rated the ETC best in overall performance and adequacy of airway patency and ventilation compared with the PTLA, LMA, and oral airway–mask. The ETC was associated with the fewest problems with ventilation and was the most preferred by a majority of EMTs.[30] In a retrospective study of 12,020 cases of nontraumatic cardiac arrest, Tanigawa and Shigematsu[32] found the ETC to have a better first attempt insertion rate (82.4%) than either the esophageal gastric tube airway or the LMA.

The ETC was effective when used by paramedics as a rescue airway in 16 of 17 failed rapid-sequence intubations in a study involving trauma patients with severe head injuries meeting criteria for rapid-sequence intubation (n = 114).[36]

A recent case report demonstrated easy insertion of the ETC in a trapped patient. Confined space and oropharyngeal bleeding prevented tracheal intubation and necessitated ETC insertion through the open windshield of the car. The ETC facilitated airway control and maintenance of continuous positive-pressure ventilation during extrication of the patient[12] (Figure 3).

The most recent prehospital study evaluated a

Figure 4. Replacement of Combitube with fiberoptic-guided endotracheal intubation

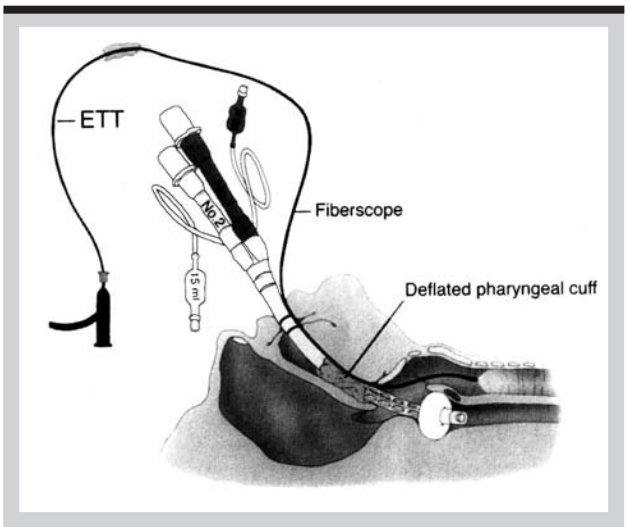

(Used with permission from Suresh M, Wali A. Failed Intubation in obstetrics: airway management strategies. *Anesthesiol Clin North Am.* 1998;16:477-498.)

physician-only urban emergency medical service and confirmed the value of the ETC for airway control when direct laryngoscopy and intubation were impossible (5/83 [6%]). However, the authors also reported 2 cases in which the ETC did not work as a first choice airway (2/89 [2%]). The study highlighted the value of the ETC when access to the patient's head is limited. In addition, the authors reported no difference between epinephrine administered into the esophagus via tracheal port No. 2 of the ETC at 10 times the standard dose and that instilled through a tracheal tube at the standard dose.[46] However, further study is necessary before these results are applied to use of the ETC for drug administration.

• *Potential use for combat casualties.* The ETC could prove to be of benefit for the airway management of combat casualties. A recent study demonstrated the value of lecture, videotape, and manikin training for advanced airway management by combat corpsmen.[47] The simplicity of the ETC in combination with the self-inflating bulb could provide a viable rescue ventilation[1] option for combat casualties.[48-50]

• *Exchange of the ETC for a definitive airway.* After resolving the critical airway event, the esophageally placed ETC usually is exchanged for a definitive airway in most patients. However, ventilatory support can be withdrawn gradually if adequate spontaneous ventilation returns and the patient's condition permits. When extubation criteria are confirmed, the mouth is suctioned and the oropharyngeal cuff is deflated completely, while the distal cuff remains inflated. The patient then can breathe around the ETC.[8] Supplemental oxygen should be continued as required. Once criteria for extubation are confirmed, the distal cuff is deflated and the ETC is removed with continuous suctioning via the open-ended tracheal lumen No. 2.[8]

Neuromuscular blockade, sedation, or both are indicated if the patient becomes alert or agitated during effective ETC-facilitated ventilation but does not meet criteria for extubation.[8] If an extended period of ventilatory support is expected, the ETC must be exchanged for a definitive airway. After several hours of ETC ventilation, venous stasis and swelling of the tongue may be noted.[50] This complication usually is harmless and resolves soon after ETC removal in most patients (A. Ovassapian, oral communication, 1994). To minimize swelling during extended use, the volume of the oropharyngeal cuff should remain inflated with an amount necessary to just maintain an airtight seal.[5]

The ETC can be exchanged for a conventional ETT using direct laryngoscopy[12,20,28] (Figure 3G), fiberoptic-assisted oral intubation[28,50,51] (Figure 4), fiberoptic-assisted nasal intubation,[52] percutaneous dilational cricothyrotomy,[53] percutaneous dilational tracheotomy,[54] or a surgical airway.[19,22,45] Caution should be used when attempting to exchange the ETC using blind percutaneous needle tracheotomy because accidental transtracheal needle aspiration of free air from the distal cuff of the ETC in the esophagus can be misinterpreted as proper tracheal positioning of the needle.[54]

During ETC exchange, the distal cuff of the ETC should remain inflated until tracheal intubation is confirmed to prevent aspiration should regurgitation occur.[8] The technique of exchanging an alternative airway with a definitive airway without interruption of ventilation is unique and is of special value in patients with severe pulmonary dysfunction.[38]

ETC limitations and contraindications

The ETC has specific limitations[7,14,38] (Table 2) and contraindications[8,14,46] (Table 3) that should be understood before using it. Particular contraindications include use of the ETC SA 37F in patients fewer than 4 ft tall, elective use of the ETC in patients with known esophageal pathology or who have ingested caustic substances, and use of the ETC with an intact gag reflex or a clenched jaw. Patients with an intact gag reflex or a clenched jaw cannot be intubated with the ETC unless they first receive intravenous sedation or a neuromuscular blocking agent. The ETC is not beneficial in cases of glottic or subglottic obstruction. It is effective only for alleviating supraglottic airway obstructions. Resolving a

Table 2. Limitations of the esophageal-tracheal Combitube (ETC)

- ETC is only effective in alleviating a supraglottic airway obstruction. Esophageally placed ETC cannot alleviate glottic (eg, laryngeal spasm, massive edema, tumor, abscess) or subglottic airway obstructions.[7]
- Sharp teeth can damage cuffs.[55]
- Cannot be used in a patient with a clenched jaw.[8]
- No pediatric size is available.[8]
- Difficult to insert ETC in patients with rigid cervical collars in place.[56]
- 37F SA limited for use in patients >4 ft (120 cm) tall and <6 ft (183 cm) tall.[57]
- 41F ETC limited for use in patients >6 ft (183 cm) tall.[57]

SA = small adult

Table 3. Contraindications to the use of the esophageal-tracheal Combitube (ETC)

- Should not be used in glottic or subglottic obstruction. Obstruction of this type requires an endotracheal tube, transtracheal jet ventilation, or a surgical airway.[7]
- Should not be used in cases of upper airway obstruction secondary to foreign body aspiration, severe glottic edema, or epiglottitis.[8]
- Should not be used electively after ingestion of caustic substances or in patients with known esophageal disease (eg, hiatal hernia, esophageal varices, esophagitis).[14]
- ETC is not for use in patients with an intact gag reflex, irrespective of the level of consciousness.[14]

Table 4. Reported complications associated with use of the esophageal tracheal Combitube

Reference	Type of report/no. of patients	Complication (no. of occurrences)
Rumball and MacDonald,[30] 1997	Prehospital prospective study/88	Bleeding from oral pharynx and supraglottic area (2); no instance of gastric or esophageal rupture or significant injury to the upper airway observed
Tanigawa and Shigematsu,[32] 1998	Prehospital retrospective study/1,594	Aspiration (1); oropharyngeal bleeding (4); hypopharyngeal bleeding (2); vocal cord injury (1); esophageal perforation (1); bleeding from esophageal diverticulum (1); subcutaneous emphysema (1)
Lefrancois and Dufour,[39] 2002	Prehospital prospective study/831	Aspiration (1); inadequate ventilation (25); subcutaneous emphysema (18); pneumonia (5); bronchitis (4); no esophageal lesions or injury reported (0)
Richards,[45] 1998	Case report/1	Piriform sinus perforation with subcutaneous emphysema (1)
Green and Beger,[60] 1994	Case report/2	Malposition of the ETC in 2 patients; ETC placed esophageally per manufacturer's instructions. No ventilation possible via either port; ETC pulled back 2-3 cm with subsequent successful ventilation via blue esophageal port No. 1
Klein et al,[58] 1997	Case report/8	Elective use in a patient with preexisting esophageal disease resulting in a case of esophageal perforation with subcutaneous emphysema (1)
Vézina et al,[59] 1998	Prehospital retrospective study/1,139	Proximal and distal cuffs overinflated: subcutaneous emphysema (8); autopsies performed (4): esophageal laceration (2); multiple superficial esophageal lacerations (1); no lesion found (1)

Figure 5. Improper placement of Combitube

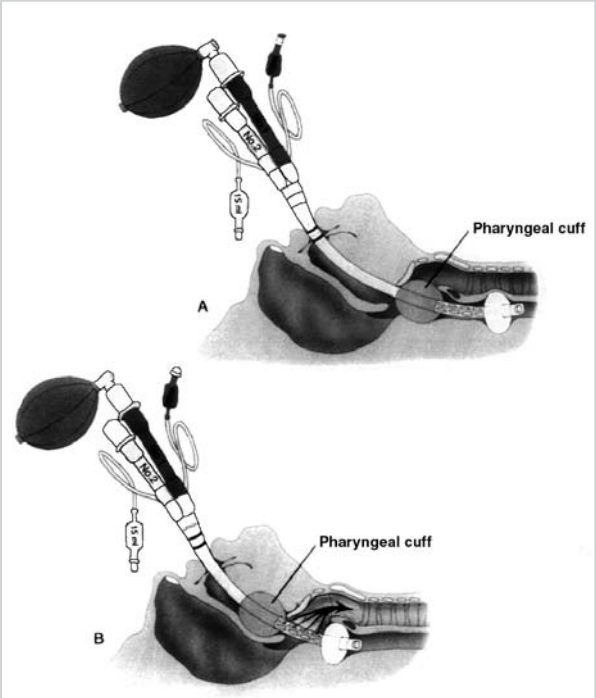

(A) Excessive insertion depth of the Combitube, causing obstruction of the glottic opening. Ventilation is not possible. (B) Readjustment of Combitube. The Combitube is pulled back 2 to 3 cm (indicated by the 2 black rings), and ventilation through lumen No. 1 allows the passage of gas from the side orifices into the trachea.

(Used with permission from Suresh M, Wali A. Failed intubation in obstetrics: airway management strategies. *Anesthesiol Clin North Am.* 1998;16:477-498.)

glottic or subglottic obstruction requires placement of an airway device below the obstruction with an ETT, transtracheal jet ventilation, or a surgical airway.

Reported ETC complications

Although infrequent, complications with the ETC have been reported (Table 4).[32,45,58,59] ETC malfunction is evident when ventilation is not possible through either port. The cause of this is deep esophageal insertion of the ETC (Figure 5A).[60,61] Deep insertion causes partial obstruction of the pharyngeal perforations (ventilating eyes)[61] or glottic occlusion by the proximal oropharyngeal cuff.[60] This infrequent problem is resolved by withdrawing the ETC 2 to 3 cm in small incremental movements until the lungs can be ventilated through the blue pharyngeal port No. 1[60] (see Figure 5B). Tanigawa and Shigematsu[32] found that even though some level of limitations, disadvantages, or complications were apparent with all the airway devices they reviewed, the ETC had comparatively fewer limitations, disadvantages, and complications overall.

The few reports of soft tissue perforation associated with use of the ETC merit discussion (see Table 4).[32,58,59] Piriform sinus perforation and subcutaneous emphysema secondary to difficult blind ETC insertion following cannot ventilate–cannot intubate in a case of cardiac arrest from angioedema and tongue swelling was reported.[45] In this situation, use of the ETC 37F SA may have been beneficial. The report does not document whether the ETC was inserted blind or with a laryngoscope.[45] Insertion of the smaller ETC 37F SA in conjunction with a laryngoscope is easier and less traumatic to soft tissues and reduces intubation failures.[41,62] The report that associated the elective use of the ETC with 1 case of iatrogenic esophageal perforation in a patient with a known hiatal hernia[58] has been challenged.[57,63] The patient was not well anesthetized, during which time 5 different airway tools were inserted. The elective use of the ETC in patients with known esophageal pathology is discouraged.[57]

Two esophageal lacerations reported in the review of prehospital use of the ETC by Vézina et al[59] revealed excessive overinflation with 20 to 40 mL of air used in the distal cuff. However, esophageal perforation did not influence the patient's outcome.[59] In a follow-up cadaver study, Vézina et al[64] studied esophageal and tracheal distortion observed with ETC insertion and concluded that distention resulting from inflation of the distal cuff could lead to esophageal injuries. However, improper use of the ETC by overfilling the cuffs reported in their original article is a more probable cause.[59] Distal cuff inflation of 10 ± 1 mL is often adequate for distal sealing of the ETC.[5,38] In the study by Tanigawa and Shigematsu,[32] it could not be determined whether the ETC or the automatic CPR compression device or a combination of the two was the cause of 1 case of esophageal perforation and 1 case of subcutaneous emphysema (see Table 4).

It has been reported that the ETC 37F SA is easier to use than the ETC 41 F (due to its smaller size) and seems to be less traumatic to soft tissues.[62] Therefore, the recommendation that the ETC SA be used in patients 4 to 6 ft tall (120-183 cm),[37,57] along with application of the "Lipp maneuver,"[1,65] may further decrease the incidence of soft tissue injury.

Oczenski et al[66] reported that blind insertion of the ETC caused an increased release of catecholamines with a pronounced stress response, and they recommended that precautions be taken when it is used in patients at

risk of hypertensive bleeding. However, the findings of recent studies[4,6,67,68] stand in contrast with the findings of Oczenski et al[66] and showed no statistical difference in hemodynamics between ETC and ETT.

Conclusion

An analysis of trauma victims revealed that more than 30% of deaths were related to airway or breathing dysfunction and to extracranial hemorrhage.[69] Research has revealed that airway intubation potentially is capable of extending a trauma victim's ability to tolerate circulatory arrest.[70] Furthermore, prehospital tracheal intubation improves survival in patients with blunt injury and a field Glasgow Coma Scale score of 8 or less, especially in patients with severe head injury.[71] Early intubation of trauma victims, along with early intravenous access in the field, is recommended for improving patient outcome.[72]

The ETC is recommended by the American Heart Association as a class IIa device compared with bag-valve-mask ventilation (class IIb).[73] Since 1992, the ETC has been included as an appropriate option to cannot ventilate–cannot intubate situations in the American Society of Anesthesiologists Difficult Airway Algorithm[38,74,75] and the Guidelines of the American Heart Association for Advanced Cardiac Life Support.[76] It also is recommended by the International Liaison Committee on Resuscitation in collaboration with the American Heart Association.[77] In addition, it is recommended by the Advanced Life Support Working Group of the European Resuscitation Council.[78] It can be stored easily on difficult airway carts[37] and advanced cardiac life support carts, since it is available in a rigid tray, a roll-up kit (both kits containing all accessories), and as a single kit (containing the ETC only).[38] However, even though it is recommended as an effective rescue airway, the ETC remains underused for ventilation during CPR.[79]

The use of the ETC in combination with the self-inflating bulb,[26,80-83] portable carbon dioxide detector,[84] and ventilation bag offer a standard of airway control comparable to that afforded by tracheal intubation, albeit with the requirement for much less training. Successful rescue ventilation[1] with the ETC has been reported when other rescue airways have failed.[16,35] While direct laryngoscopy for tracheal intubation remains the preferred method of airway control, the ETC deserves strong consideration as a rescue airway and as a primary airway in certain clinical situations.[9-13,16,20-36] In the esophageal (common) or tracheal (rare) position, the ETC provides excellent oxygenation and ventilation and application of high ventilation pressures and decreases risk of aspiration.[4-6,8,9,44] It should be available for use by all healthcare personnel who provide emergency airway management. Use of the ETC for rescue ventilation[1] and airway control in conjunction with other lifesaving measures potentially could improve survival for victims of trauma and nontraumatic cardiac arrest from the prehospital arena through care received at medical facilities. The increased use of the ETC in prehospital care[12,22,24,28-30,33,34,36,39,45,46] increases the possibility of emergency patients arriving at the hospital with the ETC in place, which makes it all the more important that anesthesia providers be familiar with how it functions.

REFERENCES

1. Rich J, Mason A, Bey T, Krafft P, Frass M. The critical airway, rescue ventilation, and the Combitube: Part 1. *AANA J.* 2004;72:17-27.
2. Frass M, Frenzer R, Zdrahal F, Hoflehner G, Porges P, Lackner F. The esophageal tracheal Combitube: preliminary results with a new airway for CPR. *Ann Emerg Med.* 1987;16:768-772.
3. Frass M, Frenzer R, Rauscha F, Weber H, Pacher R, Leithner C. Evaluation of esophageal tracheal Combitube in cardiopulmonary resuscitation. *Crit Care Med.* 1987;15:609-611.
4. Hartmann T, Krenn CG, Zoeggeler A, Hoerauf K, Benumof JL, Krafft P. The oesophageal-tracheal Combitube small adult. *Anaesthesia.* 2000;55:670-675.
5. Urtubia R, Aguila C, Cumsille M. Combitube. A study for proper use. *Anesth Analg.* 2000;90:958-962.
6. Hoerauf K, Harman T, Acimovic S, et al. Waste gas exposure to sevoflurane and nitrous oxide during anaesthesia using the oesophageal-tracheal Combitube small adult. *Br J Anaesth.* 2001;86:124-126.
7. Benumof J. The ASA Difficult Airway Algorithm: new thoughts and considerations. In: Hagberg C, ed. *Handbook of Difficult Airway Management.* Philadelphia, Pa: Churchill Livingstone; 2000:31-48.
8. Mest DR. The esophageal-tracheal Combitube. In: Hanowell LH, Waldron RJ, Hwang JCF, eds. *Airway Management.* Philadelphia, Pa: Lippincott-Raven; 1996:213-222.
9. Frass M, Frenzer R, Rauscha F, Schuster E, Glogar D. Ventilation with the esophageal tracheal Combitube in cardiopulmonary resuscitation: promptness and effectiveness. *Chest.* 1988;93:781-784.
10. Yurino M. Esophageal tracheal Combitube overcomes difficult intubation: flexion deformity of the cervical spine due to rheumatoid arthritis. *J Anesth.* 1994;8:233-235.
11. Staudinger T, Tesinsky P, Klappacher G, et al. Emergency intubation with the Combitube in two cases of difficult airway management. *Eur J Anaesthesiol.* 1995;12:189-193.
12. Knacke A. Case report: prehospital airway management of a trapped person with polytrauma [in German]. *Rettungsdienst.* 2001;24:994-996.
13. Della Puppa A, Pittoni G, Frass M. Tracheal esophageal Combitube: a useful airway for morbidly obese patients who cannot intubate or ventilate. *Acta Anaesthesiol Scand.* 2002;46:911-913.
14. Frass M. The Combitube: esophageal/tracheal double lumen airway. In: Benumof JL, ed. *Airway Management: Principles and Practice.* St Louis, Mo: Mosby; 1996:444-454.
15. Enlund M, Miregard M, Wennmalm K. The Combitube for failed intubation: instructions for use. *Acta Anaesthesiol Scand.* 2001;45:127-128.
16. Mercer M. Respiratory failure after tracheal extubation in a patient with halo frame cervical spine immobilization: rescue therapy

using the Combitube airway. *Br J Anaesth.* 2001;86:886-891.

17. Hoak S, Koestner A. Esophageal tracheal Combitube in the emergency department. *J Emerg Nurs.* 1997;23:347-350.
18. Frass M, Frenzer R, Mayer G, et al. Mechanical ventilation with the esophageal tracheal Combitube (ETC) in the intensive care unit. *Arch Emerg Med.* 1987;4:219-225.
19. Wiltschke C, Kment G, Swoboda H, et al. Ventilation with the Combitube during tracheostomy. *Laryngoscope.* 1994;104:763-765.
20. Frass M, Frenzer R, Zahler J, Ilias W, Leithner C. Ventilation via the esophageal tracheal Combitube in a case of difficult intubation. *J Cardiothorac Anesth.* 1987;1:565-568.
21. Bigenzahn W, Pesau B, Frass M. Emergency ventilation using the Combitube in cases of difficult intubation. *Eur Arch Otorhinolaryngol.* 1991;248:129-131.
22. Eichinger S, Schreiber W, Heinz T, et al. Airway management in a case of neck impalement: use of the oesophageal tracheal Combitube airway. *Br J Anaesth.* 1992;68:534-535.
23. Klauser R, Roggla G, Pidlich J, Leithner C, Frass M. Massive upper airway bleeding after thrombolytic therapy: successful airway management with the Combitube. *Ann Emerg Med.* 1992;21:431-433.
24. Atherton GL, Johnson JC. Ability of paramedics to use the Combitube in prehospital cardiac arrest. *Ann Emerg Med.* 1993;22:1263-1268.
25. Banyai M, Falger S, Roggla M, et al. Emergency intubation with the Combitube in a grossly obese patient with bull neck. *Resuscitation.* 1993;26:271-276.
26. Baraka A, Salem R. The Combitube oesophageal-tracheal double lumen airway for difficult intubation. *Can J Anaesth.* 1993;40:1222-1223.
27. Staudinger T, Brugger S, Watschinger B, et al. Emergency intubation with the Combitube: comparison with the endotracheal airway. *Ann Emerg Med.* 1993;22:1573-1575.
28. Wagner A, Roeggla M, Roeggla G, et al. Emergency intubation with the Combitube in a case of severe facial burn [letter]. *Am J Emerg Med.* 1995;13:681-683.
29. Liao D, Shalit M. Successful intubation with the Combitube in acute asthmatic respiratory distress by a Parkmedic. *J Emerg Med.* 1996;14:561-563.
30. Rumball C, MacDonald D. The PTL, Combitube, laryngeal mask, and oral airway: a randomized prehospital comparative study of ventilatory device effectiveness and cost-effectiveness in 470 cases of cardiorespiratory arrest. *Prehosp Emerg Care.* 1997;1:1-10.
31. Kulozik U, Georgi R, Krier C. Intubation with the Combitube-TM in massive hemorrhage from the locus Kieselbachii [in German]. *Anasthesiol Intensivmed Notfallmed Schmerzther.* 1996;31:191-193.
32. Tanigawa K, Shigematsu A. Choice of airway devices for 12,020 cases of nontraumatic cardiac arrest in Japan. *Prehosp Emerg Care.* 1998;2:96-100.
33. Blostein PA, Koestner AJ, Hoak S. Failed rapid sequence intubation in trauma patients: esophageal tracheal Combitube is a useful adjunct. *J Trauma.* 1998;44:534-537.
34. Ochs M, Vilke GM, Chan TC, Moats T, Buchanan J. Successful prehospital airway management by EMT-Ds using the Combitube. *Prehosp Emerg Care.* 2000;4:333-337.
35. Klein U, Rich J, Seifert A, Tesinsky P. Use of the Combitube as a rescue airway during a case of "can't ventilate–can't intubate (CVCI)" in the operating room when a laryngeal mask failed. *Difficult Airway.* 2002;3:5-7.
36. Ochs M, Davis D, Joyt D, Bailey D, Marshall L, Rosen P. Paramedic-performed rapid sequence intubation of patients with severe head injuries. *Ann Emerg Med.* 2002;40:159-167.
37. Yardy N, Hancox D, Strang T. A comparison of two airway aids for emergency use by unskilled personnel. *Anaesthesia.* 1999;54:181-183.
38. Frass M, Agro F, Rich J, Krafft P. The all-in-one concept for securing the airway and adequate ventilation. *Semin Anesth Perioperative Med Pain.* 2001;20:202-211.
39. Lefrancois D, Dufour D. Use of the esophageal tracheal Combitube by basic emergency medical technicians. *Resuscitation.* 2002;52:77-83.
40. Mercer M. An assessment of the airway from aspiration of oropharyngeal contents using the Combitube airway. *Resuscitation.* 2001;51:135-138.
41. Wissler R. The esophageal-tracheal Combitube. *Anesthesiol Rev.* 1993;4:147-152.
42. Deroy R, Ghoris M. The Combitube elective anesthetic airway management in a patient with cervical spine fracture. *Anesth Analg.* 1998;87:1441-1442.
43. Frass M, Lackner F, Frenzer R, Hofbauer R. Analysis of 500 uses of the Combitube: safety, efficacy, and maximum ventilatory pressures during routine surgery. *Difficult Airway.* 2001;2:84-90.
44. Hartmann T, Hoauf K, Faybik P, Lorenz V, Krafft P. Randomized controlled trial comparing Combitube SA TM, laryngeal tube TM, Proseal TM for ventilatory support during laparoscopic surgery [abstract]. *Br J Anaesth.* 2002;88:31a.
45. Richards C. Piriform sinus perforation during esophageal-tracheal Combitube placement. *J Emerg Med.* 1998;16:37-39.
46. Rabitsch W, Schellongowski P, Staudinger T, et al. Comparison of a conventional tracheal airway with the Combitube in an urban emergency medical services system run by physicians. *Resuscitation.* 2003;57:27-32.
47. Calkins MD, Robinson TD. Combat trauma airway management: endotracheal intubation versus laryngeal mask airway versus Combitube use by Navy SEAL and Reconnaissance combat corpsmen. *J Trauma.* 1999;46:927-932.
48. General considerations of forward surgery. In: Bowen TE, Bellamy RF, eds. *Emergency War Surgery*. 2nd ed. Washington, DC: US Government Printing Office; 1988:1-9.
49. *Combat Life Savers Course: Instructor's Manual*. A edition. Washington, DC: US Government Printing Office. 1995.
50. Rich J, Frass M. Battlefield airway management: overview of a proposed system to improve airway management in the first echelon of the battlefield. *Asian Arch Anaesthesiol Resuscitation.* 2001;54:1-19.
51. Krafft P, Roeggla M, Fridirch P, Locker G, Frass M, Benumof J. Bronchoscopy via a redesigned Combitube in the esophageal position. *Anesthesiology.* 1997;86:1041-1045.
52. Gaitini L, Vaida S, Somri M, Fradis M, Ben-David B. Fiberoptic-guided exchange of esophageal-tracheal Combitube in spontaneously breathing versus mechanically ventilated patients. *Anesth Analg.* 1999;88:193-196.
53. Mallick A, Quinn AC, Bodenham AR, Vucevic M. Use of the Combitube for airway maintenance during percutaneous dilatational tracheostomy. *Anaesthesia.* 1998;53:249-255.
54. Letheren M, Parry N, Slater R. A complication of percutaneous tracheostomy whilst using the Combitube for airway control. *Eur J Anaesthesiol.* 1997;81:464-466.
55. Baskett PJ, Dow A, Nolan J, Maull K. Upper airway control. In: *Practical Procedures in Anesthesia and Critical Care.* St Louis, Mo: Mosby; 1995:68-84.
56. Mercer M, Gabbott D. Insertion of the Combitube airway with the cervical spine immobilised in a rigid cervical collar. *Anaesthesia.* 1998;53:971-974.
57. Krafft P, Nikolic A, Frass M. Esophageal rupture associated with the use of the Combitube [letter]. *Anesth Analg.* 1998;87:1457.
58. Klein H, Williamson M, Sue-Ling H, Vucevic M, Quinn A. Esophageal rupture associated with the use of the Combitube. *Anesth Analg.* 1997;85:937-939.
59. Vézina D, Lessard MR, Bussieres J, Topping C, Trepanier CA. Complications associated with the use of the Esophageal-Tracheal Combitube. *Can J Anaesth.* 1998;45:76-80.

60. Green K, Beger T. Proper use of the Combitube [letter]. *Anesthesiology.* 1994;81:513.

61. Wafai Y, Salem M, Baraka A, Joseph N, Czinn E, Paulissian R. Effectiveness of the self-inflating bulb for verification of proper placement of the esophageal tracheal Combitube. *Anesth Analg.* 1995;80:122-126.

62. Walz R, Davis S, Panning B. Is the Combitube a useful emergency airway device for anesthesiologists [letter]? *Anesth Analg.* 1999;88: 233.

63. Walz R, Bund M, Meier P, B P. Esophageal rupture associated with the use of the Combitube [letter]. *Anesth Analg.* 1998;87:228.

64. Vézina D, Trepanier CA, Lessard MR, Bussieres J. Esophageal and tracheal distortion by the Esophageal-Tracheal Combitube: a cadaver study. *Can J Anaesth.* 1999;46:393-397.

65. Frass M, Staudinger T, Losert H, Krafft P. Airway management during cardiopulmonary resuscitation: a comparative study of bag-valve-mask, laryngeal mask airway and Combitube in a bench model. *Resuscitation.* 1999;43:80-81.

66. Oczenski W, Krenn H, Dahaba A, et al. Hemodynamic and catecholamine stress responses to insertion of the Combitube, laryngeal mask airway or tracheal intubation. *Anesth Analg.* 1998;88: 1389-1394.

67. Gaitini LA, Vaida SJ, Mostafa S, et al. The Combitube in elective surgery: a report of 200 cases. *Anesthesiology.* 2001;94:79-82.

68. Panning B, Sterz F. Hemodynamic and catecholamine stress responses to insertion of the Combitube, laryngeal mask or tracheal intubation [letter]. *Anesth Analg.* 2000;90:231.

69. Papadopoulos IN, Bukis D, Karalas E, et al. Preventable prehospital trauma deaths in a Hellenic urban health region: an audit of prehospital trauma care. *J Trauma.* 1996;41:864-869.

70. Pepe P, Eckstein M. Reappraising the prehospital care of the patient with major trauma. *Emerg Med Clin North Am.* 1998;16:1-15.

71. Winchell R, Hoyt D. Endotracheal intubation in the field improves survival in patients with severe head injury. *Arch Surg.* 1997;132:592-597.

72. Regel G, Stalp M, Lehmann U, Seekamp A. Prehospital care, importance of early intervention on outcome. *Acta Anaesthesiol Scand Suppl.* 1997;110:71-76.

73. Barnes T, MacDonald D, Nolan J, et al. Airway devices. *Ann Emerg Med.* 2001;37(4 suppl):S145-S151.

74. Practice guidelines for management of the difficult airway: a report by the American Society of Anesthesiologists Task Force on Management of the Difficult Airway. *Anesthesiology.* 1993;78:597-602.

75. Benumof JL. The American Society of Anesthesiologists' Management of the Difficult Airway Algorithm and explanation-analysis of the algorithm. In: Benumof JL, ed. *Airway Management: Principles and Practice.* St Louis, Mo: Mosby; 1996:143-158.

76. Adult advanced cardiac life support. *JAMA.* 1992;268:2199-2241.

77. European Resuscitation Council. Part 6: Advanced cardiovascular life support. Section 3: Adjuncts for oxygenation, ventilation, and airway control. *Resuscitation.* 2000;46:115-125.

78. de Latorre F, Nolan J, Robertson C, Chamberlain D, Baskett P. European Resuscitation Council Guidelines 2000 for Adult Advanced Life Support: A statement from the Advanced Life Support Working Group(1) and approved by the Executive Committee of the European Resuscitation Council. *Resuscitation.* 2001;48:211-221.

79. Grayling M, Wilson I, Thomas B. The use of the laryngeal mask airway and Combitube in cardiopulmonary resuscitation: a national survey. *Resuscitation.* 2002;52:183-186.

80. Nunn J. The oesophageal detector device [letter]. *Anaesthesia.* 1988;43:804.

81. Wafai Y, Salem MR, Joseph NJ, Czinn EA, Paulissian R. Use of the self-inflating bulb with the esophageal tracheal Combitube [letter]. *Anesth Analg.* 1995;81:1117-1118.

82. Wafai Y, Crinn EA, Salem MR, Baraka A. Proper placement of the esophageal tracheal Combitube. *Anesthesiology.* 1995;82:1304-1305.

83. Salem MR, Baraka A. Confirmation of tracheal intubation. In: Benumof JL, ed. *Airway Management: Principles and Practice.* St Louis, Mo: Mosby; 1996:531-560.

84. Thomas S, Wedel S, Wayne M. Oxygenation, ventilation, and monitoring. In: Soreide E, Grande C, eds. *Prehospital Trauma Care.* New York, NY: Marcel Dekker; 2001:255-272.

AUTHORS

James M. Rich, CRNA, MA, is a staff anesthetist in the Department of Nurse Anesthesia, Baylor University Medical Center, Dallas, Tex, and an adjunct instructor in Emergency Medicine Education at the University of Texas Southwestern Medical Center, Dallas.

Andrew M. Mason, MB, BS, MRCS, LRCP, is an immediate care physician with the Suffolk Accident Rescue Service, Ipswich, England.

Tareg A. Bey, MD, is associate clinical professor, Department of Emergency Medicine, University of California Irvine, Orange, Calif.

Peter Krafft, MD, PhD, is professor, Department of Anesthesiology and General Intensive Care, University of Vienna, Vienna, Austria.

Michael Frass, MD, is professor of Medicine, Department of Internal Medicine I, University of Vienna, Vienna, Austria.

ACKNOWLEDGMENTS

Michael Frass, MD, is patent holder of the Combitube and receives royalties from Tyco-Healthcare-Nellcor. James Rich, CRNA, MS, is the founder and executive director of the Airway Education and Research Foundation (www.AirwayEducation.com) and the creator of the SLAM Universal Emergency Airway Flowchart. Rich receives an honorarium from the Airway Education and Research Foundation for teaching at SLAM Emergency Airway Workshops. Andrew M. Mason, MB, BS, MRCS, LRCP, is the adviser in Pre-hospital care to Intavent Orthofix, Ltd, Maidenhead, England, the distributors of the LMA in the United Kingdom. This is an unsalaried post, but Mason receives occasional payment from the company for advisory work in connection with use of the LMA in the prehospital environment.